

## Case report

# Treatment of the Non-Traumatic Auricular Pseudocyst With Aspiration and Intralesional Steroid Injection

Hayriye KARABULUT <sup>1</sup>, Baran ACAR <sup>1</sup>, Kenan Selçuk TUNCAY <sup>1</sup>, Taner TANYILDIZLI <sup>2</sup>,  
Ayşe Serap KARADAĞ <sup>2</sup>, Servet GÜREŞÇİ <sup>3</sup>, Rıza Murat KARASEN <sup>1</sup>

<sup>1</sup> Keçiören Training and Research Hospital Department of Otorhinolaryngology, ANKARA

<sup>2</sup> Keçiören Training and Research Hospital Department of Dermatology, ANKARA

<sup>3</sup> Keçiören Training and Research Hospital Department of Pathology, ANKARA

## ÖZET

### Aurikuler psödokist tedavisinde aspirasyon ve intralezyoner steroid enjeksiyonu

Aurikuler psödokist, aurikulanın ön yüzüne yerleşen, nadir görülen benign bir hastalıktır. Klinik olarak bu hastalık aurikula üst ön yüzde belirgin ağrısız, fluktuan şişlik ile karakterizedir. Etiyoloji net olmamakla birlikte minör travmalar bu hastalığın nedeni olarak suçlanmaktadır. Literatürde bu hastalığın tedavisi çok çeşitlidir. İnsizyonel drenaj veya iğne aspirasyonunu takiben baskılı sargı en sık uygulanan metodlardan biridir, fakat bu metodun rekürrens oranları yüksektir. Önceki çalışmalarda belirtildiği gibi kavitenin kimyasal veya mekanik obliterasyonu tedavinin başarısı için gereklidir. Rekürren vakalara, anterior duvar eksizyonu gibi daha invaziv cerrahi yaklaşımlar gerekmektedir. Burada non-rekürren ve nontravmatik aurikular psödokistin iğne aspirasyonu ve intralezyonel steroid enjeksiyonu ile tedavisini sunduk. İntralezyonel steroid, minimal invaziv bir teknik olup ofis ortamında kolaylıkla uygulanabilen ve steroide bağlı komplikasyonların olmadığı başarılı kozmetik sonuçlar veren bir uygulamadır.

**Anahtar Kelimeler :** Auriküler psödokist, auriküler rekonstrüksiyon

## ABSTRACT

The pseudocyst of auricle is a rare and a benign condition of the ear that is located in the anterior aspect of the auricle. Clinically, this condition presents as a painless, prominent, fluctuant swelling on the upper anterior surface of the auricle. Although etiology is unclear, low-grade minor trauma was blamed as an inducing factor of this condition. In the literature treatment of this condition varies widely. Incisional drainage or needle aspiration followed by a compressive dressing is one of the most commonly applied methods but, this method of treatment has high recurrence rates. Chemical or mechanical obliteration of the cavity is necessary for a successful treatment as reported in the previous studies. At recurrent cases more invasive surgical approaches such as anterior wall excision are necessary. We present a treatment of a non-traumatic and non-recurrent auricular pseudocyst by needle aspiration and intralesional steroid injection therapy. This minimally invasive technique is easy to apply in an office setting and give a good cosmetic outcome without complications associated with intralesional steroid administration.

**Key Words :** Auricular pseudocyst, auricular reconstruction

## INTRODUCTION

The pseudocyst of auricle is a rare and benign condition of the ear that is caused by intracartilaginous collection of serous fluid in the anterior aspect of the auricle. The auricular pseudocyst has a cavity that is not lined by epithelium. The term pseudocyst of the auricle was first defined by Hartman in 1846<sup>1</sup>.

Although this condition occurs in both sexes, it occurs predominantly in men as noted by Grossman and Cohen<sup>2</sup>. Most cases are seen unilaterally but bilateral cases have also been defined<sup>2</sup>. Clinically, this condition presents a painless, prominent, fluctuant swelling on the upper anterior surface of the auricle with normal or delicately inflamed overlying skin.

Although low-grade minor trauma such as hard pillows, stereo headphones and motorcycle helmets

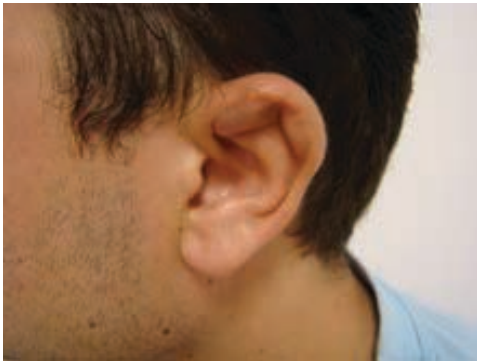was blamed as an inducing factor of this condition, etiology is unclear and most cases do not have a history of acute trauma<sup>3</sup>.

The aim of the treatment is to restore the original auricular structure while removing the cystic lesion. In the literature, treatment of this condition varies widely. Most accomplished results were obtained by incisional drainage, followed by chemical and mechanical obliteration such as pressure dressing with button bolsters and compression suture therapy. Chemical obliteration is performed by intracartilaginous trichloroacetic acid<sup>4</sup> and intralesional corticosteroid<sup>3,5</sup>. If the incision and drainage or aspiration were performed alone, multiple recurrences and ear deformities could be seen. In 1985, Okuma reported three patients who were successfully treated with needle

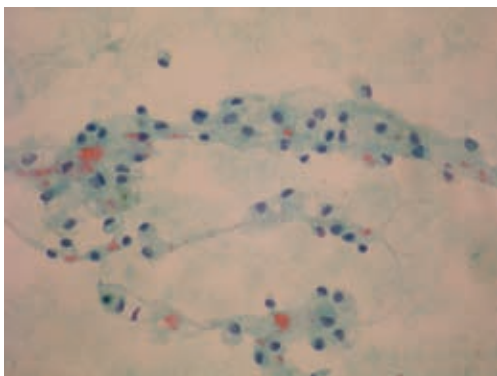
aspiration, followed by local steroid injection<sup>5</sup>. The other method of treatment is intramuscular corticosteroid therapy<sup>3</sup>. Here, we present the treatment of an auricular pseudocyst by needle aspiration and local steroid injection in a nontraumatic and nonrecurrent case.

## CASE

A 22-year-old man was admitted to our clinic with a history of painless swelling of the left auricle at the superior scaphoid fossa for two weeks. The patient had no history of microtrauma associated with occupational or behavioural activities and declined any history of trauma. On physical examination, the patient had two prominent, fluctuant swelling at the left superior scaphoid fossa with a normal overlying skin. The lesions that affected the superior scaphoid fossa were 16x16 mm and 10x10 mm in diameter, respectively (Figure 1). The diagnosis of the lesion depended on the typical history and clinical findings.



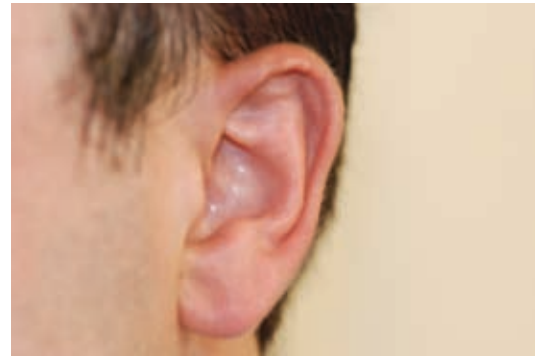**Figure 1.** The lesions that affected the superior scaphoid fossa were 16x16 mm and 10x10 mm in diameter, respectively



**Figure 2.** There were foamy macrophages in a proteinaceous background (PapX40)

The treatment was made by local anesthesia (%1 w/v lidocaine, 1 ml). The anesthetized area was penetrated with a sterile needle and all the

pseudocystic collection was aspirated into an empty injector. Using another injector, steroid fluid (triamcinolone suspension) was injected into the pseudocystic cavities until they achieved the original sizes. Then gauze was pressed onto the auricular surface to stop the bleeding. The aspirated fluid was examined histopathologically. There were foamy macrophages in a proteinaceous background (PapX40) (Figure 2). Four weeks after the intervention, there was no recurrence of the pseudocyst with an enviable cosmetic outcome (Figure 3).



**Figure 3.** Four weeks after the intervention, there was no recurrence of the pseudocyst with an enviable cosmetic outcome

## DISCUSSION

Although histopathologic findings are well described in previous reports<sup>2</sup> the precise mechanism of pseudocyst formation is yet unknown. It is shown that there is no proliferation of inflammatory cells. Eosinophilic degeneration and necrosis of the cartilage can occur in some areas. In our case, fine needle aspiration biopsy of the cyst revealed foamy macrophage in a proteinaceous background. The differential diagnosis of this condition includes subperichondral haematoma secondary to trauma, cellulitis and relapsing polychondritis. Despite its unclear etiology, most of the physicians accepted that chronic low-grade trauma is the major etiological factor of this condition. However in our case, the patient had no history of microtrauma associated with occupational or behavioural activities as previously reported by Salgado<sup>6</sup> and Tuncer<sup>7</sup>.

The aim of the treatment should provide best cosmetic outcome for the patient while using minimal invasive technique that provides no recurrence. In the literature, various treatment methods of auricular pseudocyst have been applied. Although incisional drainage or needle aspiration followed by a compressive dressing is one of the most commonly applied methods this

therapy is inadequate due to its high recurrence rate. Chemical or mechanical obliteration of the cavity is necessary for a successful treatment as reported in the previous studies. Miyamoto et al<sup>9</sup> applied intracystic steroid injections to treat their patients.

In addition, when the treatment is planned with simple aspiration or incision and drainage, recurrence rates increase. Recurrent auricular pseudocysts were treated by several authors with reasonable success by achieving aspiration followed by either oral or intralesional steroid administration<sup>3,9</sup>. But intralesional steroid administration has some disadvantages such as skin pigmentation changes, skin, soft tissue and cartilage atrophy and potential systemic side effects. In our case, this side effects were not seen postoperatively after 4 weeks of follow up.

At recurrent cases, more invasive surgical approaches are necessary to prevent recurrences

and poor cosmetic appearances. Anterior wall excision was defined for recurrent cases<sup>10</sup>. In this technique if the posterior wall is weak, cosmetic deformities such as 'floppy ear deformity' may occur. Tuncer et al. described one stage treatment with surgical curettage, followed by intralesional fibrin glue administration for obliteration of the cystic cavity<sup>7</sup>.

We suggested that the needle aspiration and intralesional steroid injection therapy are minimally invasive, easy to apply in an office setting and give a good cosmetic outcome. Complications associated with intralesional steroid administration such as skin, soft tissue and cartilage atrophy, skin pigmentation changes and potential systemic side effects were not seen in our case. Eventually we think that, in non-traumatic and non-recurrent cases, this technique can be performed confidently and successfully.

## REFERENCES

- Hartmann A. Über Cystenbildung in der Ohrenmuschel. Arch Ohren Nasen Kehlkopfheilkd 1846;15:156-66.
- Cohen PR, Grossman ME. Pseudocyst of the auricle: case report and world literature review. Otolaryngol Head Neck Surg 1990;116: 1202-4.
- Glamb R, Kim R. Pseudocyst of the auricle. J Am Acad Dermatol 1984;11: 58.
- Cohen PR, Katz BE. Pseudocyst of the auricle: successful treatment with intracartilaginous trichloroacetic acid and button bolsters. Dermatol Surg Oncol 1991;17: 255-8.
- Okuma M. Treatment for pseudocyst of the auricle. Jpn Dermatol 1985;95: 390 (in Japanese).
- Salgado CJ, Hardy JE, Mardni S, Dockery JM, Matthews MS. Treatment of auricular pseudocyst with aspiration and local pressure. J Plastic Reconstructive, Aesthetic Surgery 2006;59: 1450-2.
- Tuncer S, Basterzi Y, Yavuzer R. Recurrent auricular pseudocyst: a new treatment recommendation with curettage and fibrin glue. Dermatol Surg 2003;29 :1080-3.
- Hegde R, Bhargava S, Bhargava KB. Clinical records: pseudocyst of the auricle: a new method of treatment. J Laryngol Otol 1996;110: 767-9.
- Miyamoto H, Oida M, Onuma S, Uchiyama M. Steroid injection therapy for pseudocyst of the auricle. Acta Derm Venereol 1994;74: 140-2.
- Secor CP, Farrel HA, Haydon RC. Auricular endochondral pseudocysts: diagnosis and management. Plast Reconstr Surg 1999;103: 1451-7.

---

### Correspondence :

Hayriye KARABULUT M.D.  
Keçiören Training and Research Hospital, Ankara  
e-mail: drhayriye@hotmail.com  
Arrival date : 02.12.2008  
Acceptance date : 20.01.2009