

Low-Temperature Bipolar Radiofrequency Ablation (Coblation) of the Tongue Base for Supine-Position-Associated Obstructive Sleep Apnea

Mehmet Ali Babademez^a Bulent Ciftci^b Baran Acar^a Muge Fethiye Yurekli^a
Hayriye Karabulut^a Aydin Yilmaz^b Rıza Murat Karasen^a

^aDepartment of Otorhinolaryngology, Kecioren Training and Research Hospital, and

^bAtatürk Chest Disease and Chest Surgery Training and Research Hospital, Sleep Lab, Ankara, Turkey

Key Words

Coblation · Supine-position-associated sleep apnea ·
Obstructive sleep apnea syndrome · Tongue base

Abstract

Objective: To assess the effectiveness of low-temperature bipolar radiofrequency ablation for Coblation of the tongue base in the multilevel management of supine-position-associated obstructive sleep apnea syndrome (OSAS). **Study Design and Setting:** A retrospective analysis of the data of 16 subjects undergoing uvulopalatopharyngoplasty and tongue base Coblation. The efficacy of the procedure was investigated on the basis of polysomnographic results. **Results:** The success rate was 62.5% in 16 patients who underwent surgery for OSAS, with decreases in the mean Apnea Hypopnea Index of 20.1–8.9. The success rate was separately evaluated according to the subjects' posture. A rate of 87.5% was found for the supine position, while the rate was 56.6% in non-supine positions. The minimum postoperative O₂ saturation was significantly increased for REM and non-REM stage 3 sleep rates. **Conclusion:** It is important to evaluate the relation of the disease to the body position in sleep ap-

nea subjects. Coblation of the tongue base is an applicable method of therapy for patients who have sleep apnea that is more marked in the supine position.

Copyright © 2010 S. Karger AG, Basel

Introduction

Obstructive sleep apnea is a disease that affects about 3% of the general population and can have fatal results when untreated [1]. Nasal continuous positive airway pressure (CPAP) is the gold standard and primary method of therapy in obstructive sleep apnea syndrome (OSAS). Compliance to CPAP therapy is lower when there is a decrease in disease severity [2]. Curative surgical treatment is particularly important for subjects in whom CPAP therapy cannot be applied. The tendency to collapse is increased in OSAS patients when lying in the supine position, as this diminishes the nasopharyngeal and oropharyngeal openings. The disease is position-dependent in more than half of subjects [3]. It is well known that posterior glossal narrowing is associated with supine-position-dependent OSAS [4].

Regardless of the position dependency, various rates of success have been achieved through techniques like suspension of the tongue base [5] by monopolar radiofrequency application on the base of the tongue [6], or the submucosal minimally invasive excision technique applied to the tongue base [7].

In our study, we aimed to evaluate the rate of success of volume reduction surgery on the tongue base, for the purpose of increasing the airway opening at the hypopharyngeal region, in supine-position-dependent subjects with posterior glossal narrowing.

Material and Methods

Tongue base volume reduction operations using the Coblator II device (Arthrocare, Sunnydale, Calif., USA) with bipolar radiofrequency ablation (Coblation) and expansion sphincter pharyngoplasty were performed on 37 supine-position-dependent subjects with Apnea Hypopnea Index (AHI) values of >10 at Ankara Kecioren Training and Research Hospital between March 2007 and April 2008. The study was approved by the institution's ethics committee.

Participants were excluded from the study if they had any of following: (1) simple snoring; (2) absence of excessive daytime sleepiness; (3) a ratio of supine-position AHI:non-supine position AHI of <2 ; (4) a non-supine-position AHI value of <5 , but were able to continue with positional therapy; (5) maxillomandibular retrognathia on the lateral cephalometric evaluation; (6) had undergone any type of oropharyngeal surgery; (7) significant body weight changes (changes in weight exceeding 10%) detected through diagnostic polysomnography during examinations in the 6th month of therapy.

Some of the 37 subjects were excluded from the study due to the following reasons: 4 female subjects were excluded for the purpose of homogenizing the group of subjects; 2 were excluded due to having histories of diseases involving operations for sleep apnea within the previous year (uvulopalatopharyngoplasty in one subject and uvulectomy and nasal surgery in the other); 2 subjects were excluded due to small SNB angles found on the cephalometric examination; 8 subjects were excluded due to extra surgical attempts (septoplasty, etc.); 5 subjects were excluded for significant changes in BMI at the time of diagnosis and in the 6th month of the therapy. Thus, 16 male supine-position-dependent OSAS patients were retrospectively examined.

Tests involving sleep effectiveness values of $<75\%$ or total sleeping times of <4 h were considered invalid, while tests involving posture distributions of <1 h for each of the supine or non-supine positions were also discarded from the study results.

All subjects were offered the option of nasal CPAP as the first choice instead of surgery. Subjects were selected for surgery based on polysomnography, an otorhinolaryngological examination (including flexible endoscopy), and the Müller maneuver and lateral cephalometry (as decided by the Kecioren Sleep Council, comprising ENT specialists, a pulmonologist who analyzed the polysomnograms, and an orthodontist).

All subjects underwent preoperative counseling, and informed consent was obtained. These subjects were classified ac-

ording to the relation between the tongue base and the vallecula using flexible nasopharyngoscopy (classification of Dreher et al. [8]). According to this classification, subjects with a tongue base touching (grade 2) or pushing (grade 3) the vallecula, as detected by endoscopic examination, were included in the study.

The expansion sphincter pharyngoplasty procedure (as published by Pang et al. [9]) and tongue base Coblation were performed on all the subjects. The Coblation procedure, a modification of the submucosal minimally invasive lingual excision (SMILE) procedure defined by Maturro and Mair [10], was performed as described later.

Subjects were examined and evaluated clinically on the 15th day, as well as in the 1st, 3rd and 6th months, and evaluated polysomnographically in the 6th month following surgery. BMI was measured in all subjects pre- and postoperatively.

Preoperative and postoperative data obtained from subjects were compared statistically using the Wilcoxon test.

Sleep Study

The sleep records of consecutive subjects referred for overnight polysomnography to rule out OSAS at the Sleep Center of Atatürk Hospital for Chest Diseases were evaluated. Standard overnight polysomnography was performed in all subjects using the Compumedics® Voyager Digital Imaging E-series system (Compumedics, Melbourne, Vic., Australia). Polysomnography included the following variables: 4 electroencephalogram channels, electrooculogram, bipolar surface electromyograms of the submental and bilateral tibialis anterior muscles, and position sensors to record body position and movements. Respiratory monitoring consisted of nasal and oral airflow measures (oronasal cannula), a tracheal microphone, thoracic and abdominal respiratory efforts (piezo belts), finger pulse oximetry, an electrocardiogram, in addition to simultaneous video recording.

Sleep staging was performed according to the standard criteria set by the American Academy of Sleep Medicine [11]. Apnea was defined as a complete cessation of airflow for at least 10 s. Hypopnea was defined as a decrease in airflow of at least 50%, accompanied by 3% desaturation and a reduction in chest wall movement and/or arousal. The AHI was defined as the number of apneas and hypopneas per hour of sleep.

Operative Procedure: Tongue Base Ablation with Bipolar Radiofrequency

The procedure was performed under general anesthesia with the subject in the supine position. The authors performed the procedure by utilizing nasotracheal intubation, with a Jennings mouth gag within the oral cavity to keep the mouth open.

The black silk suture was tied from the tip of the tongue to the suspension of the tongue in preparation for the Coblation procedure (fig. 1).

Tissue was excised by moving the coblator wand in an anterior-to-posterior direction and a superior-to-inferior direction from the section starting at 2/3 of the tongue over the midline extending to the vallecula, using a coblator in such a manner that the lingual neurovascular bundle remained inferolateral. Temporary silk sutures were used to retract the wound edges laterally.

Due to the inferolateral location of the lingual arteries at the tongue base, care was taken to stay within 1–1.5 cm of the midline and medial to the previously marked boundaries (fig. 2). The wound was not sutured, and left for primary recovery.

Table 1. Pre- and postoperative polysomnograph parameters

	Pre-operative	Post-operative	p value
AHI total	20.1 ± 10.5	8.9 ± 6.5	0.001
AHI supine	43.1 ± 25.6	11.1 ± 15.2	<0.001
AHI non-supine	9.0 ± 6.5	5.1 ± 4.9	0.079
Average O ₂ saturation, %	92.2 ± 1.6	92.6 ± 1.8	0.856
Minimum O ₂ saturation, %	84.6 ± 3.4	86.6 ± 2.0	0.022
REM sleep rates	16.5 ± 5.1	21.8 ± 6.9	0.049
Non-REM stage 3 sleep rates	16.0 ± 6.1	25.6 ± 6.6	0.004

This procedure took approximately 25–30 min to perform. A prophylactic antibiotic and systemic corticosteroid were given.

Results

The mean age of subjects was 41.3 ± 10.5 years. The mean preoperative BMI was 29.6 ± 2.5 and the postoperative BMI was 29.5 ± 2.6 ($p = 0.346$; not significant). Some polysomnography parameters are shown in table 1. The subject group had mild-to-severe OSAS with a mean preoperative AHI of 20.1 ± 10.5 (95% CI 6.7–39.7). The mean postoperative AHI was 8.9 ± 6.5 (95% CI 1.2–18.6). This result represents a 55.7% decrease from the preoperative AHI. The success rate, which is defined as >50% reduction in the AHI and a postoperative AHI of <20 events per hour, was 62.5%. The surgical cure rates according to supine and non-supine positions were 87.5 and 56.3%, respectively.

The status of oxygenation during sleep was evaluated using the average O₂ saturation and minimum O₂ saturation. The average O₂ saturation increased in 7 subjects, decreased in 6 subjects and remained the same in 3 subjects, with no statistical significance ($p = 0.856$). However, the minimum postoperative O₂ saturation decreased in 2 subjects and increased in 14 subjects, and this difference was significant ($p = 0.022$). Sleep quality was measured on the basis of the rate of REM and non-REM stage 3 periods. REM sleep decreased in 4 subjects postoperatively, but increased in 12 subjects ($p = 0.049$). Non-REM stage 3 decreased in 2 subjects and increased in 14 subjects ($p = 0.004$).

Figure 3 shows the preoperative and postoperative appearances of the tongue base in the same patient using a flexible nasopharyngoscope.

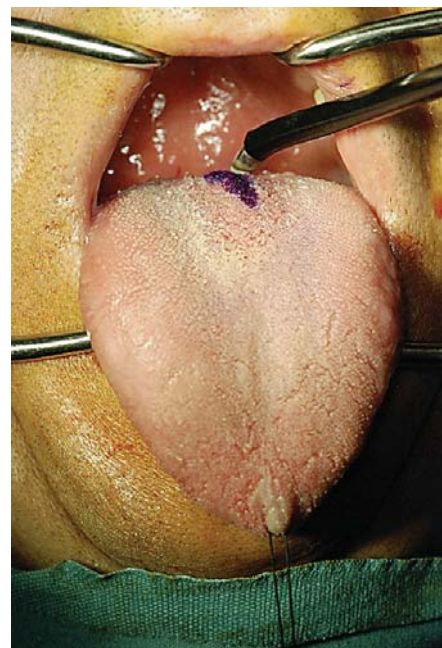

Fig. 1. Black silk suture tied from the tip of the tongue to the suspension of the tongue.

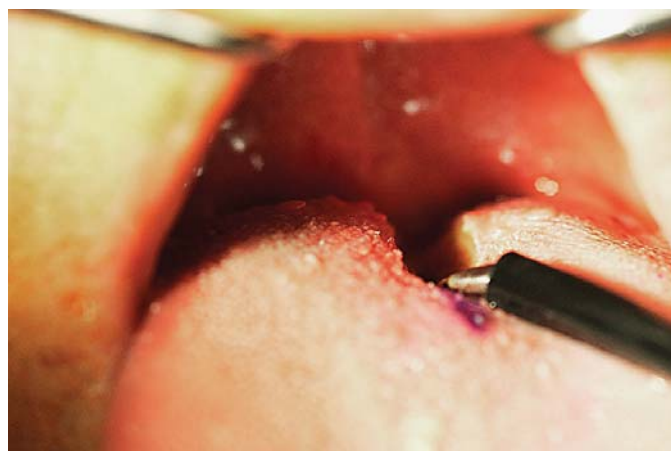

Fig. 2. Care was taken to stay within 1–1.5 cm of the midline and medial to the previously marked boundaries.

Four adverse effects were observed in 16 subjects. These were pain necessitating the use of analgesic for more than 5 days (5/16), difficult swallowing that lasted longer than 10 days after surgery (2/16), difficulty swallowing solid foods for more than 30 days after operation (9/16), and halitosis for more than 30 days after the operation (1/16).

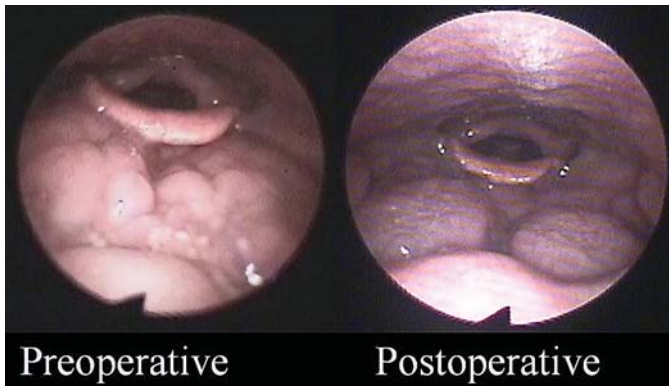


Fig. 3. Preoperative and postoperative appearances of the tongue base in the same patient.

Discussion

Studies have indicated that more than half of OSAS patients are positional patients (PPs). Supine-position AHI values occur at a rate of at least twice that of the non-supine AHI values in the case of PPs [12].

It is known that sleep in the supine position increases the intensity of OSAS due to the effects of gravity. The most important factor that causes narrowing in the upper respiratory tract system under the effects of gravity is the tongue [13]. There are publications indicating higher rates of tongue base hypertrophy in PPs compared to non-PP subjects [3, 4]. Thus, a differentiation has to be made before the surgical operation between different types of position-dependent OSAS patients. In addition, the pathophysiological effect of the tongue base should be considered when selecting the best surgical method for position-dependent subjects. The AHI value shows variations in PPs on different nights. Up until now, position dependency of the disease has not been taken into consideration in published studies where surgical success was evaluated. The surgical success in our study was evaluated while considering the effect of position on the disease.

Surgical procedures, such as RFBOT (unipolar submucosal radiofrequency tongue base reduction), tongue base suspension and SMILE, are applied to reduce blockage in OSAS patients with hypopharyngeal obstructions. Among these procedures, application of RFBOT has advantages, such as the ease of use and repeatability, besides its disadvantages of limited success and mechanical limitations in surgery, its probability of causing severe necrosis and scar contractions, as well as airway obstructions

that may require tracheotomy, and the fact that it may cause unexpected results like an abscess [14]. Tongue base suspension has a high therapeutic success rate; however, it has some disadvantages, such as the risk of damaging the lingual neurovascular bundle, breakages in the suture used, infections, pain that cannot be controlled by pain medication, side effects (like dysphagia and odynophagia), as well as unexpected results that may require speech therapy afterwards [15]. SMILE has adverse effects, like hypoglossal nerve injury and edema on the tongue base in the postoperative period, although it is less invasive and more successful than RFBOT [7]. Lingual artery damage is also a serious side effect of this method, but its incidence has diminished significantly with the ultrasonographically guided method utilized by Mauro and Mair [10].

Bipolar radiofrequency technology is also known as Coblation. The bipolar radiofrequency energy excites the electrodes in a conductive medium, usually made of saline solution, to create a plasma field of highly ionized particles that is able to break down intercellular bonds in the tissue, causing minimal damage to the surrounding healthy tissue because of the low temperature. This technology makes it possible to extract significant amounts of tissue without causing necrosis and scar contraction at the tongue base. Figure 3 shows the preoperative and postoperative appearance of the tongue base in the same patient, using a flexible nasopharyngoscope.

It has been emphasized that multilevel surgery oriented towards obstructed regions in the upper airway generates more successful results. It is a known fact that narrowing occurs at the level of the tongue base along the airway in the case of supine-position OSAS. In general, due to this reason, a response cannot be obtained to palatal surgery [16]. Thus, we utilized the tongue base intervention in addition to palatal surgery due to the importance of adjunct and Coblation uvulopalatopharyngoplasty.

AHI values obtained in patients with supine-position-related OSAS by polysomnography are directly related to the supine-position sleep periods of patients during the test. Sleeping in the supine position for longer periods leads to higher total AHI values, while lower AHI values are generated by shorter periods in the supine position. Thus, AHI values obtained separately for sleep in the supine and non-supine positions during the whole night may generate more reliable and repeatable results [17]. We compared the disease intensity by taking AHI values obtained by polysomnography with regard to the supine position, which were found to be directly related to the pe-

riod of time they had slept in the supine position during the test. Sleeping in the supine position for longer periods results in an increase in total AHI values, while shorter sleeping times generate lower AHI values. For this reason, measurement of AHI values separately for supine and non-supine positions is a preferable method, which yields more consistent results with better repeatability than a single overall AHI measurement for the whole night.

Following our surgical procedure, there was an improvement in REM and non-REM stage 3 sleep, emphasizing the increase in sleep quality.

AHI values in the supine and non-supine positions were obtained on a separate basis during polysomnography performed in the pre- and postoperative periods. According to our evaluation, a significant improvement was observed in the supine-position AHI values in 87.5% of the patients, while the rate of improvement in the non-supine position was 56.3%. Although it is incorrect to

compare the rates of success with other studies due to the lack of classification of severity according to the position, we believe that our method has an acceptable rate of success when considering the rates of success in RFBOT (between 20% [6] and 83% [18]), tongue base suspension (80% [5]) and SMILE (65% [7]).

Conclusion

We believe that position-based AHI values provide a more realistic approach in accordance with AHI values obtained overnight for the purpose of evaluating the pre- and postoperative severity of the disease in sleep apnea patients. The tongue base Coblation operation is an effective method of treatment in patients with severe disease, especially in the supine position, and it has an acceptable frequency of side effects.

References

- Young T, Palta M, Dempsey J, Skatrud J, Weber S, Badr S: The occurrence of sleep disordered breathing in middle-aged adults. *N Engl J Med* 1993;328:1230–1235.
- Lojander J, Maasilta P, Partinen M, Brander PE, Salmi T, Lehtonen H: Nasal-CPAP, surgery and conservative management for treatment of obstructive sleep apnea syndrome, a randomized study. *Chest* 1996;110:114–119.
- Richard W, Kox D, den Herder C, Laman M, Van Tinteren H, de Vries N: The role of sleep position in obstructive sleep apnea syndrome. *Eur Arch Otorhinolaryngol* 2006; 263:946–950.
- Kim HY, Bok KH, Dhong HJ, Chung SK: The correlation between pharyngeal narrowing and the severity of sleep-disordered breathing. *Otolaryngol Head Neck Surg* 2008;138: 289–293.
- Woodson BT: A tongue suspension suture for obstructive sleep apnea and snorers. *Otolaryngol Head Neck Surg* 2001;124:297–303.
- Woodson BT, Nelson L, Mickelson S, Huntly T, Sher A: A multi-institutional study of radiofrequency volumetric tissue reduction for OSAS. *Otolaryngol Head Neck Surg* 2001; 125:303–311.
- Friedman M, Soans R, Gürpınar B, Lin HC, Joseph N: Evaluation of submucosal minimally invasive lingual excision technique for treatment of obstructive sleep apnea/hypopnea syndrome. *Otolaryngol Head Neck Surg* 2008;139:378–384.
- Dreher A, de la Chaux R, Klemens C, Werner R, Baker F, Barthlen G, Rasp G: Correlation between otorhinolaryngologic evaluation and severity of obstructive sleep apnea syndrome in snorers. *Arch Otolaryngol Head Neck Surg* 2005;131:95–98.
- Pang KP, Woodson BT: Expansion sphincter pharyngoplasty: a new technique for the treatment of obstructive sleep apnea. *Otolaryngol Head Neck Surg* 2007;137:110–114.
- Maturo SC, Mair EA: Submucosal minimally invasive lingual excision: an effective, novel surgery for pediatric tongue base reduction. *Ann Otol Rhinol Laryngol* 2006;115: 624–630.
- Iber C, Ancoli-Israel S, Chesson A, Quan SF: The AASM Manual for the Scoring of Sleep and Associated Events: Rules Terminology and Technical Specifications, ed 1. Westchester, American Academy of Sleep Medicine, 2007.
- Oksenberg A, Silverberg DS: The effect of body posture on sleep-related breathing disorders: facts and therapeutic implications. *Sleep Med Rev* 1998;2:139–162.
- Ye J, Han D, Wang J, Yang Q, Lin Y, Wang J, Li Y: Computer-assisted fiberoptic pharyngoscopy in obstructive sleep apnea syndrome. *ORL J Otorhinolaryngol Relat Spec* 2007;69:153–158.
- Stuck BA, Starzak K, Verse T, Hormann K, Maurer JT: Complications of temperature-controlled radiofrequency volumetric tissue reduction for sleep-disordered breathing. *Acta Otolaryngol* 2003;123:532–535.
- Omur M, Ozturan D, Elez F, Unver C, Derman S: Tongue base suspension combined with UPPP in severe OSA patients. *Otolaryngol Head Neck Surg* 2005;133:218–223.
- Richard W, Kox D, den Herder C, Van Tinteren H, de Vries N: One stage multilevel surgery (uvulopalatopharyngoplasty, hyoid suspension, radiofrequency ablation of the tongue base with/without genioglossus advancement), in obstructive sleep apnea syndrome. *Eur Arch Otorhinolaryngol* 2007; 264:439–444.
- Acar B, Karabulut H, Babademez MA, Ciftci B, Karasen RM: Evaluation of submucosal minimally invasive lingual excision technique for treatment of obstructive sleep apnea/hypopnea syndrome. *Otolaryngol Head Neck Surg* 2009;140:281.
- Kao YH, Shnayder Y, Lee KC: The efficacy of anatomically based multilevel surgery for obstructive sleep apnea. *Otolaryngol Head Neck Surg* 2003;129:327–335.