

# Anomalous Relationship of the Retromandibular Vein to the Facial Nerve as a Potential Risk Factor for Facial Nerve Injury During Parotidectomy

Mehmet Ali Babademez, MD, Baran Acar, MD, Emre Gunbey, MD,  
Hayriye Karabulut, MD, and Rıza Murat Karasen, MD

**Abstract:** Finding and protecting the facial nerve are a challenge for the surgeon performing parotid surgery. The abnormal relationship between the retromandibular vein and facial nerve and its branches may increase the risk of facial nerve injury during surgery. In this clinical report, we have reported a 41-year-old female patient with pleomorphic adenoma undergoing superficial parotidectomy, and we have discussed a new variation of facial nerve–retromandibular vein relationship.

**Key Words:** Retromandibular vein, facial nerve, parotidectomy

(*J Craniofac Surg* 2010;21: 801–802)

The biggest fear of surgeons performing parotid surgery is causing facial nerve injury. As facial nerve injury is an important cause of morbidity, exploration and protection of the facial nerve during parotid surgery are important. Numerous landmarks have been described to locate the facial nerve. These include the mastoid processes, the tragal pointer, the posterior belly of the digastric muscle, and the tympanomastoid suture line. The main trunk of the facial nerve may be identified by retrograde tracing of the distal branches. Another method is to find the retromandibular vein in the neck, to trace it upward, and to expose the inferior division of the nerve crossing the vein. This method is particularly recommended in cases with tumors located posteriorly between the mastoid process and the parotid.<sup>1</sup> Variations in the localization of the facial nerve and the retromandibular vein and the tumor tissue extending into the deep branches of the facial nerve have effects on the risk of facial injury during parotid surgery.<sup>2</sup> Surgeons should know the probable variations of the facial nerve. We discuss a new variation with high risk for facial nerve injury and the relationship between the facial nerve and the retromandibular vein.

## CLINICAL REPORT

A 41-year-old woman presented with a painless left parotid mass. The patient had noticed the mass 6 years ago, and it had grown

From the Kecioren Training and Research Hospital Department of Otorhinolaryngology, Ankara, Turkey.

Received November 16, 2009.

Accepted for publication December 11, 2009.

Address correspondence and reprint requests to Emre Gunbey, MD,

Kecioren Training and Research Hospital, Department of Otorhinolaryngology, Pinarbasi mahallesi Sanatoryum caddesi Ardahan sok.no:1 Kecioren 06310, Ankara, Turkey;

E-mail: emregunbeymd@hotmail.com

The authors report no conflicts of interest.

Copyright © 2010 by Mutaz B. Habal, MD

ISSN: 1049-2275

DOI: 10.1097/SCS.0b013e3181d84027

slowly over time. On physical examination, a 3 × 3-cm mass located in the left parotid area was found. It was firm and not mobile and had not caused facial nerve paresis. No abnormalities were seen on the skin over the parotid area. There were no palpable lymph nodes in the neck. Other findings were unremarkable. On ultrasonography, she had a 30 × 30 × 35-mm solid, homogenous mass on the left parotid gland with same echogenicity of the gland. A fine-needle aspiration biopsy was performed, and the pathologic examination revealed pleomorphic adenoma.

## SURGICAL PROCEDURE

The patient underwent a left superficial parotidectomy via a lazy-S incision. The main trunk of the facial nerve was localized using standard landmarks, including tragal pointer, posterior belly of the digastric muscle, and tympanomastoid fissure. After further elevation of superficial lobe, it became visible that the confluence of the maxillary and superficial temporal veins to form the retromandibular vein occurred at an inferior level. The inferior divisions of the main trunk divided to run both deeply and superficially to, but in close contact with, the 2 tributaries of the vein (Fig. 1). The remainder of the parotidectomy was completed uneventfully. Final histopathology was reported as pleomorphic adenoma.

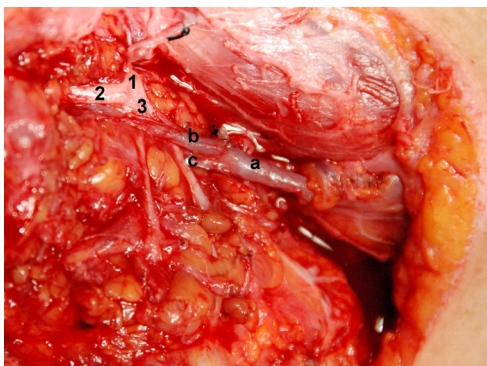
## DISCUSSION

The risk of facial nerve injury in parotid surgery is associated with the tumor being located in deep or the superficial lobe, being benign or malignant, and having a history of previous surgery. Retromandibular vein crosses the deep part of the facial nerve in many cases, and the superficial temporal vein and the maxillary vein combine and course onto the retromandibular vein, and this location is superior to the main trunk of the facial nerve. Thus, the retromandibular vein does not cause problems during parotid surgery, and it is not usually used in the exploration of the facial nerve. However, in variations where the retromandibular vein follows the superficial part of the facial nerve and its branches, the difficulty in exposure due to probable bleeding increases the risk of facial nerve injury. Besides, exploration of the facial nerve at the site of the retromandibular vein crossing the inferior division of the facial nerve is important, particularly in posteriorly located tumors.<sup>1,2</sup> The retromandibular vein is also important in the surgical treatment of mandible fractures. Kawakami et al<sup>3</sup> showed that the superficial temporal vein and the retromandibular vein are important landmarks in protecting the facial nerve and its branches during the open surgical reduction of mandibular condyle fractures.

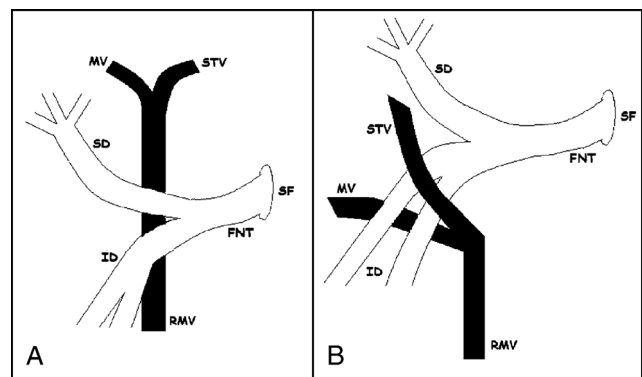
Although the relationship between the facial nerve and the retromandibular vein has been defined in anatomy publications, it has not attracted adequate attention. There are few publications on the abnormal relationship between the facial nerve and the retromandibular vein, which is not uncommon. It has been reported

in 2 series that the retromandibular vein crosses the upper superficial part of the nerve in 5% to 10% of cases.<sup>4,5</sup> In their series with 31 cadavers undergoing 54 parotid dissections, Laing and McKerrow<sup>2</sup> showed that in 69% of the cases the retromandibular vein was very close (<5 mm) to the facial nerve and that it was in the superior superficial part of the vein. In the same study, in 20% of the cases, the superior division of the facial nerve was in direct contact with the superior superficial part of the vein. The inferior division was also on the superior superficial part of the vein with a certain volume of parotid tissue. It was shown in 9% of the cases that the superficial temporal vein and branches of the maxillary vein separated from the retromandibular vein at the inferior, and it was shown that the superior division crossed these branches with direct contact. It was shown in only 1 patient that it crossed the superficial inferior division of the retromandibular vein. The nerve and the vein were in close contact in 11% of the cases.<sup>2</sup> Bhattacharyya and Varvares<sup>1</sup> reported 1 case in which the vein crossed the superior of the nerve.

The normal anatomic relationship and the variation in the facial nerve and the retromandibular vein are presented in Figures 2A and B. This was the first to be reported as a case with retromandibular vein branching inferiorly and the lower divisions crossing between the maxillary and the superficial temporal branch. There is lack of evidence in predicting the relationship of the facial nerve with the tumor and the retromandibular vein in the preoperative period. The tumor may push the pharyngeal wall to the medial at the level of the tonsillar fossa, and this may be an indicator of a deeply located tumor. The abnormal relationship between the facial nerve and the retromandibular vein may sometimes lead to nerve injury due to the unawareness of the surgeon. Apart from the variations, cases with large masses with repression of the nerve and vein may disrupt the normal nerve-vein relationship. Numerous magnetic resonance imaging (MRI) investigations have emphasized this relationship. The retromandibular vein, the external carotid artery, and the posterior belly of the digastric muscle and the tragal pointer are landmarks in exploring the facial nerve trunk in MRI investigations of parotid lesions.<sup>6</sup> Ariyoshi and Shimahara<sup>7</sup> used the line connecting the lateral surface of the ascending mandibular ramus and the retromandibular vein and the lateral surface of the posterior belly of the digastric muscle as landmarks in exploring the facial nerve and to decide whether the tumor was superficially or deeply located, using MRI. The retromandibular vein was used as a landmark for locating the lesion and the facial nerve in numerous studies with high-resolution, multidimensional, and multiplanar MRI with gadolinium administration.<sup>6-9</sup> El-Hakim et al<sup>6</sup> found that the retromandibular vein and the external carotid artery were landmarks for exposing the parotid lesion and its relationship



**FIGURE 1.** 1, Facial nerve trunk; 2, superior division; 3, inferior division; a, retromandibular vein; b, superficial temporal vein; c, maxillary vein.



**FIGURE 2.** A, The normal anatomic relationship. B, The variation in the facial nerve and the retromandibular vein. RMV indicates retromandibular vein, MV, maxillary vein; STV, superficial temporal vein; SF, stylomastoid foramen; FNT, facial nerve trunk; SD, superior division; ID, inferior division.

with the facial nerve. We performed only preoperative ultrasound and did not plan MRI as the lesion was well defined in the superficial lobe. Ultrasonography is insufficient in detecting deeply located lobe lesions. Imaging techniques such as MRI and computed tomography angiography have enabled the visualization of the vascular structures, and they have served as landmarks for locating the nerve and predicting the anomalies in the preoperative period without surprises. Preoperative MRI investigation is helpful. The importance of MRI investigation is increased by clinical experience.

We have reported a new variation of the facial nerve and the retromandibular vein during parotid surgery. Based on the previous literature, surgeons should be aware that the vein may be too close to the nerve, should know that the vein is not always at the deep part, and should be alert for variations.

## REFERENCES

- Bhattacharyya N, Varvares MA. Anomalous relationship of the facial nerve and the retromandibular vein: a case report. *J Oral Maxillofac Surg* 1999;57:75-76
- Laing MR, McKerrow WS. Intraparotid anatomy of the facial nerve and retromandibular vein. *Br J Surg* 1988;75:310-312
- Kawakami S, Tsukada S, Taniguchi W. The superficial temporal and retromandibular veins as guides to expose the facial nerve branches. *Ann Plast Surg* 1994;32:295-299
- Wang TM, Lin CL, Kuo KJ, et al. Surgical anatomy of the mandibular ramus of the facial nerve in Chinese adults. *Acta Anat (Basel)* 1991;142:126
- Kopuz C, Ilgi S, Yavuz S, et al. Morphology of the retromandibular vein in relation to the facial nerve in the parotid gland. *Acta Anat (Basel)* 1995;152:66
- El-Hakim H, Mountain R, Carter L, et al. Anatomic landmarks for locating parotid lesions in relation to the facial nerve: cross-sectional radiologic study. *J Otolaryngol* 2003;5:314-318
- Ariyoshi Y, Shimahara M. Determining whether a parotid tumour is in the superficial or the deep lobe using magnetic resonance imaging. *J Oral Maxillofac Surg* 1998;56:23-26
- Lim CY, Chang HS, Nam KH, et al. Preoperative prediction of the location of parotid gland tumors using anatomical landmarks. *World J Surg* 2008;32:2200-2203
- Imaizumi A, Kuribayashi A, Okochi K, et al. Differentiation between superficial and deep lobe parotid tumors by magnetic resonance imaging: usefulness of the parotid duct criterion. *Acta Radiol* 2009;50:806-811